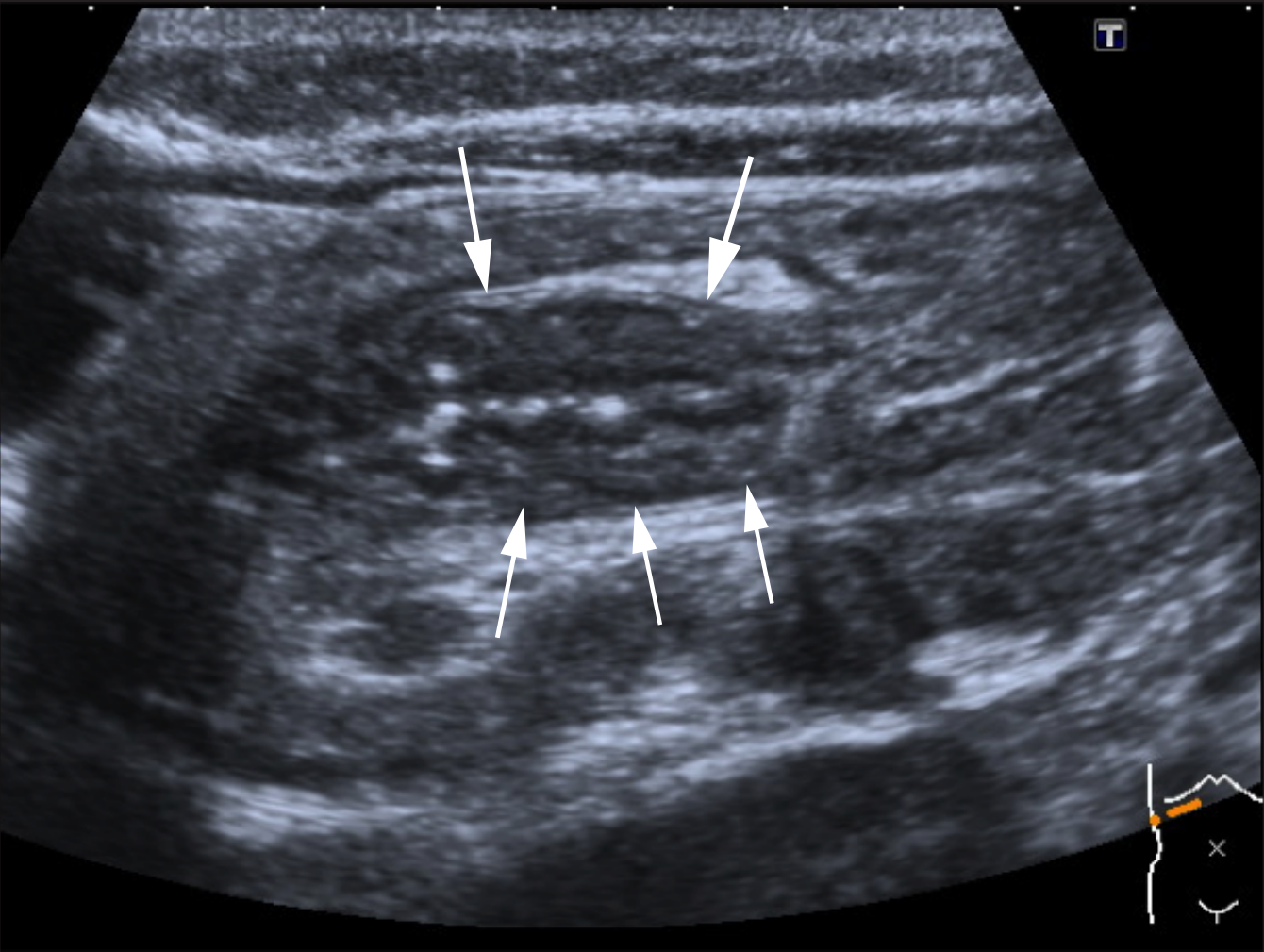


Ultrasound scan of a 6 month old boy with an intussusception who presented with blood in his motions.

Longitudinal view showing “pseudokidney” sign, so called because of its similarity to the ultrasound image of a kidney



Cross-sectional view of intussusception

